

To Splint or Not To Splint: Treating Periodontally Compromised Teeth by Improving Occlusion



E. Griffin Cole, DDS, PA
Private Practice
Austin, Texas
Phone: 512.472.3565
Fax: 512.472.1210
Email: griffincole@yahoo.com

When faced with the dilemma of how to maintain periodontally compromised teeth, restorative dentists often splint mobile teeth to stronger adjacent teeth in an effort to prolong the life expectancy of the loose teeth. A 1961 study by Glickman and colleagues clearly showed that although fixed splints provide some beneficial distribution of occlusal forces, the ideal way to alleviate excessive occlusal forces that cause tooth or teeth mobility is to remove the destructive contacts.¹ In other words, dentists must change the way the teeth contact by improving overjet and/or distributing occlusal and excursive contacts.

It is an accepted practice to splint mobile teeth, particularly lower incisors, to maintain the patient's natural dentition as long as possible.^{2,3} This is often the treatment of choice, if finances are prohibitive. However, this treatment should be planned as transitional and short-term only. Occlusal forces applied to a single tooth in a splint are transmitted to the remainder of the splinted teeth. In essence, one "bad apple" is allowed to spoil the bunch. There are numerous studies showing that the injurious effect of excessive occlusal forces on nonsplinted teeth is not transmitted to the adjacent teeth.⁴ If the destructive force is eliminated, healing can occur.

Abstract

Although splinting periodontally compromised teeth is common practice, the limitations of its effectiveness are well documented. Occlusion must always be the prime consideration when deciding how to treat a periodontally compromised dentition. Oftentimes, eliminating destructive bite interferences is all that is needed to create an environment where healing can occur. This article summarizes a 4-year history of a patient's struggle to maintain a healthy periodontium in her mandibular anterior sextant. The patient's bite patterns and excursions were carefully evaluated and improved when proper incisal guidance was created. The results were favorable and illustrated in the article. After this article is published, another year has passed and the patient's anterior teeth remain stable and further healing of the periodontium has occurred.

Learning Objectives

After reading this article, the reader should be able to:

- describe the clinical significance of splinting vs not splinting mobile teeth.
- explain the limitations and potential negative consequences of splinting teeth.
- explain the importance of occlusion in treating mobile teeth and use this knowledge to identify and eliminate destructive contacts and interferences.

The case presented in this article shows how creating proper occlusal clearance and overjet of the anterior teeth allowed the mobile teeth to heal and tighten in the periodontium.

Case Presentation

A 76-year-old woman presented with a chief complaint of severely abraded, loose, lower-front teeth (Figures 1 and 2). Her medical his-

tory, though somewhat extensive, did not directly contribute to the chief complaint. However, her dental history revealed a 10-year battle with periodontal disease and a recently placed fixed composite splint joining the 4 mandibular incisors. Also noted were numerous anterior restorations and 2 root canal therapies on teeth Nos. 8 and 10. The patient had regular, 6-month hygiene visits in the past 5 years.

Pocket depth readings within normal ranges were noted throughout the anterior region, with pockets as deep as 6 mm in the posterior quadrants. For clarity and consistency throughout this article, the focus will be on the anterior teeth.

Classification "Type 1+" mobility was noted on teeth Nos. 23 and 26, with "Type 3" mobility noted on teeth Nos. 24 and 25. The patient had an edge-to-edge incisal relationship with severe abfraction wear on teeth Nos. 23 through 26. The abraded areas had worsened during the past 5 years as described by the patient and her records, as a result of the occlusal disharmony of her anterior bite.⁵ She exhibited a cuspid-guided occlusion bilaterally coupled with anterior excursive interferences (Figure 3). Splaying of the lower incisors was also noted in excursive movements. The patient experienced no discomfort when chewing but did express concern about the obvious abrasions evident on the lower incisors. She noticed that the incisors were loose but expressed no difficulty with mastication. In October 2000, her previous dentist diagnosed approximately 70% bone loss around teeth Nos. 24 and 25 (Figure 4). In April 2002, a periodontist recommended that she splint her mandibular incisors together for stability, which led to the placement of a Ribbond-supported (Ribbond, Inc) composite splint (Figure 5) <QA: Because of our Fair Play Policy, please mention several other splints that could have been used for this procedure.>.

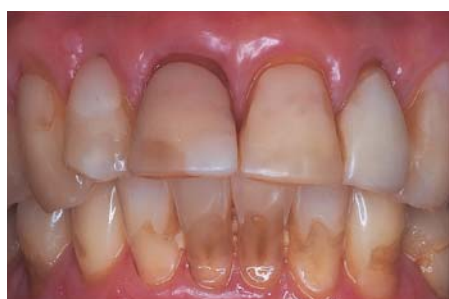

Figure 1—Preoperative anterior view.

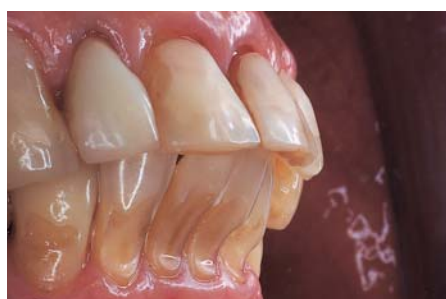

Figure 2—Preoperative, right side, anterior view. Notice the severe abfraction lesions and overjet relationship.

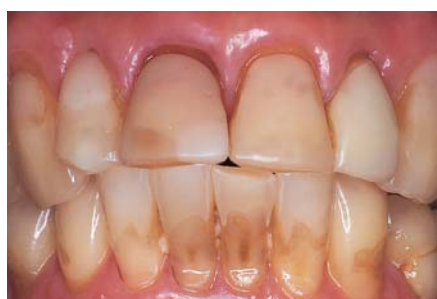

Figure 3—Anterior view showing patient just beginning to excurse into right working <QA: is this sentence finished?>. Anterior interferences do not allow for a smooth working motion.

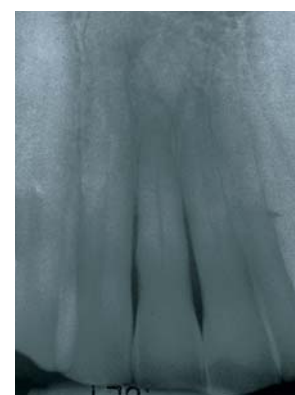


Figure 4—Radiograph of lower incisors taken in October 2000 before placement of splint and restorative work. Notice the extent of bone loss around central incisor tooth Nos. 24 and 25.

By removing the deflective contacts and allowing the 2 “bad apples” to sit independently of the adjacent teeth, healing could then occur.

Treatment Plan

Discussion regarding treatment options included creating a new

composite splint that would span from cuspid to cuspid or restoring the incisors with proper contours to

allow occlusal clearance when chewing. A detailed description of the splint, including its short-term solution as well as its potentially harmful action on the adjacent teeth, was presented to the patient.⁶

The recommended treatment was to restore the lower 4 incisors with either composite fillings or crowns and improve the anterior bite stability by creating proper

overjet and eliminating anterior excursive interferences. By removing the deflective contacts and allowing the 2 “bad apples” to sit independently of the adjacent teeth, healing could then occur.⁷ Placing permanent crowns offered a better option to create the proper overjet and provide more predictable results. A discussion regarding placement of permanent crowns on loose teeth ensued, including the strong possibility of short-term success and eventual loss of teeth. The patient understood all implications and accepted this recommended plan. After a thorough periodontal assessment and therapy, restorative treatment began. The patient’s main restorative goal was to “fix” the abraded teeth. Esthetics was not a priority for her.

Preparation

Before preparing teeth Nos. 23 through 26 for full coverage crowns, Vitrebond (3M ESPE) bases were placed in the abraded areas to add protection for the nearly exposed pulps. Conservative preparations were made, tapering the incisal edges enough to create an overjet of approximately 1.5 mm. Although new porcelain crowns were also placed on teeth Nos. 8 and 9—No. 8 had root canal therapy and No. 9 had patchwork bonding—to help create the new overjet, this was not necessary to achieve our objective. Enough room was already available to alleviate the occlusal interferences.

All margins were placed slightly supragingivally, so no retention cord was necessary. Impressions were made with Impregum (3M ESPE), and temporary crowns were made with Jet acrylic (Lang Dental Manufacturing Company, Inc) and splinted together to prevent any movement during the transition phase, which could affect the seating of the permanent crowns. The temporary bridge was cemented with Durelon (3M ESPE), and all excess cement was carefully cleaned away. Excursive movements were checked to ensure no anterior interferences of the cuspid-guided plane.

Cementation

The acrylic temporary was sectioned with a handpiece and re-

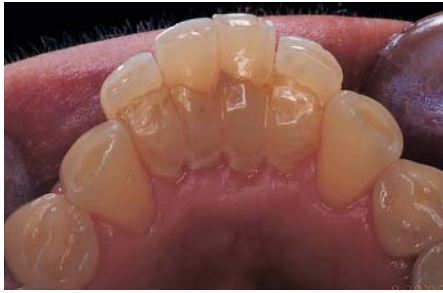
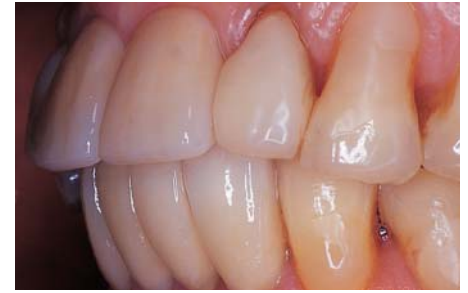
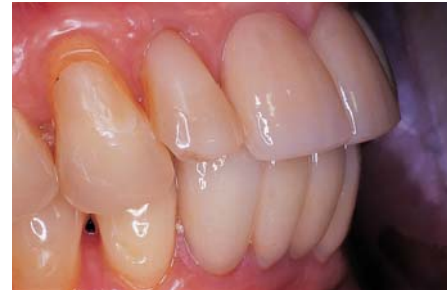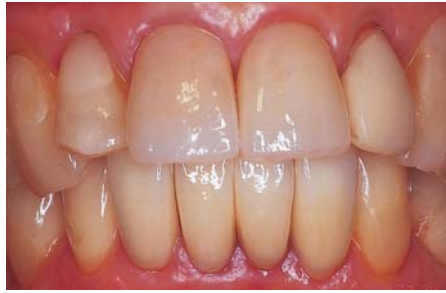Figure 5—Occlusal view of splint in place. Plaque and tartar accumulation was evident.



Figures 6 through 8—Postoperative anterior, right side and left side views. Besides improved esthetics, the overjet and overall shape of the teeth was dramatically improved.

moved with hemostats. This involved using a Midwest 245 carbide bur (Dentsply Professional) to carefully cut the temporary into separate parts. Finishing burs, like this one, cut smoothly without “jumping” during the process. The temporary was then sectionally removed with the hemostats without imparting too much stress on the mobile teeth.

The porcelain-to-gold crowns chosen for this case were Authentic Press-To-Metal Ceramics (Microstar Corporation) with Authentic 86 (The Argen Corporation) alloy (Ceramay). Authentic was chosen for its biocompatibility and low-wear features. Its impressive esthetic and durable characteristics were achieved by combining this pressable ceramic with a cast metal. The Authentic system provides an important advantage for the technician to transfer functional occlusal records from wax to ceramic with remarkable accuracy. Furthermore, the occlusal abrasion of Authentic is very similar to natural dentition.

The crowns were fitted and cemented with Fuji I Cement (GC America Inc) after conditioning the teeth with Fuji Plus Conditioner (GC America Inc). Because of the compromised pulpal condition of this patient's teeth, conditioning before cementation was an important step for avoiding postoperative sensitivity. Excursive movements were again carefully checked and interferences eliminated to allow for proper overjet/overbite clearance.

Cuspid-guided occlusion with no anterior interferences was properly established. Firm flossing contacts were created by design and, although esthetics was of little concern for the patient, a rather nice finish was realized (Figures 6 through 8).

Posttreatment Assessment

The patient returned to the

Table—Results of the Mobility Analyses From All Phases of Treatment

Year	Mobility			
	Tooth No. 23	Tooth No. 24	Tooth No. 25	Tooth No. 26
2000 (Before splint placement)	1	2	2	1
2003 (Immediately after splint removal)	1+	3	3	1+
2004 (6-months after crown cementation)	1	2	1	1




Figure 9—Radiograph of lower incisors taken in April 2004. Notice the apparent improvement in bone topography around tooth No. 24. Mobility measurements confirm improvement in attachment.

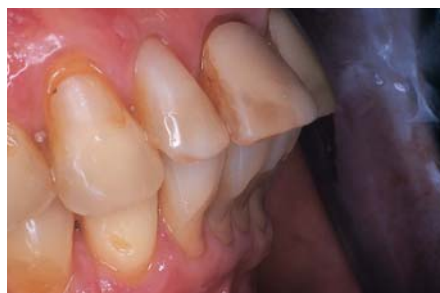

Figure 10—Preoperative view of the severe gingival abrasions and “splayed” appearance of the upper incisors.

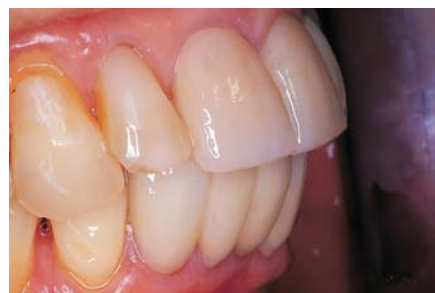

Figure 11—Postoperative view demonstrating the improved overjet and appearance of the incisors. The patient’s cuspid-guided excursions are now unimpeded by her incisors.

office 3 months later for a postoperative visit, which included reassessment of all pocket depths and a detailed tissue evaluation. A second follow-up visit was completed 3 months after that—6 months since seating permanent crowns—for reevaluation. The table above shows the results of the mobility analyses

from all phases of treatment. All postoperative photographs were taken 6 months after cementation.

Although there was little change in probing depths (eg, initial probing depths were satisfactory), there was a significant reduction in mobility readings. Teeth Nos. 23 and 26 tightened from

“Type 1+” mobility to “Type 1.” Tooth No. 24 improved from “Type 3” mobility to a “Type 2” level. Finally, tooth No. 25 improved significantly from a “Type 3” mobility reading to a “Type 1” reading. These results are particularly noteworthy because the mobility of the patient’s teeth

before placement of the Ribbond splint was less than that following splint therapy. The teeth showed the most movement immediately following splint removal.

Without radiographs it is difficult to gauge improvement when teeth are splinted. Mobility cannot be accurately measured. A radiograph taken in October 2000 shows the anterior teeth (Figure 4). Notice the amount of bone loss around tooth No. 24; only the apical one third of the root is encased in bone. A radiographic image taken in April 2004 is shown in Figure 9. Notice the improvement in bony support around tooth No. 24. The Ribbond splint was placed in April 2002 and removed in October 2003—18 months—at which time the preparations were performed. The final radiograph was taken in April 2004 (Figure 9), exactly 6 months following cementation. The patient was pleased with the results and particularly happy with the “shapely” new teeth and improved overjet (Figure 10). <AQ: There is no callout in text for Figure 11, yet you have a caption for it. We usually don’t cite Figures in Conclusion, so I moved Figure 10 here. OK? Where do you want Figure 11 called out?>

The patient was pleased with the results and particularly happy with the “shapely” new teeth and improved overjet.

Conclusion

Splinting teeth to keep the weak ones around longer is only a good plan if no other permanent options are possible. Besides creating a plaque problem, splinting can at times be detrimental to the health of the strong teeth. Removing interferences and deflective contacts is the key to creating an environment where loose teeth can “heal” and tighten in their sockets. Of course, excellent home care and

Removing the patient's splint and individualizing her incisors created the best opportunity for healing.

proper maintenance is absolutely essential for success. In this case, removing the patient's splint and

individualizing her incisors created the best opportunity for healing. Her home care became easier and

therefore more beneficial. ■

Disclosure

The author received no compensation or royalties from any of the manufacturers discussed in this article.

Acknowledgment

The author would like to thank

the ceramists at Summit Dental Laboratory of Waco, Texas for the beautifully crafted restorations presented in this article.

References

1. Glickman I, Stein RS, Smulow JB. The effect of increased functional forces upon the periodontium of splinted and non-splinted teeth. *J Periodontol.* 1961;32:290-300. <QA: Please verify reference No. 1, could not find>
2. Quirynen M, Mongardini C, Lambrechts P, et al. A long-term evaluation of composite-bonded natural/resin teeth as replacement of lower incisors with terminal periodontitis. *J Periodontol.* 1999;70(2):205-212.
3. Pollack RP. Non-crown and bridge stabilization of severely mobile, periodontally involved teeth. A 25-year perspective. *Dent Clin North Am.* 1999;43(1):77-103.
4. Serio FG, Hawley CE. Periodontal trauma and mobility. Diagnosis and treatment planning. *Dent Clin North Am.* 1999;43(1):37-44.
5. Rees JS, Jagger DC. Abfraction lesions: myth or reality? *J Esthet Restor Dent.* 2003;15(5):263-271.
6. Watkins SJ, Hemmings KW. Periodontal splinting in general dental practice. *Dent Update.* 2000;27(6):278-285.
7. Bernal G, Carvajal JC, Munoz-Viveros CA. A review of the clinical management of mobile teeth. *J Contemp Dent Pract.* 2002;3(4):10-22.

Product References

Product: Ribbond
Manufacturer: Ribbond, Inc
Address: 1402 3rd Ave.
Suite 1030
Seattle, WA 98101
Phone: 800.624.4554
Fax: 206.382.9354

Products: Vitrebond, Impregum, Durelon
Manufacturer: 3M ESPE
Address: Bldg. 275-25E-03
St. Paul, MN 55144
Phone: 800.634.2249
Fax: 612.733.2481

Product: Jet Acrylic
Manufacturer: Lang Dental
Manufacturing Company, Inc
Address: 175 Messner Dr.
Wheeling, IL 60090
Phone: 800.222.5264
Fax: 708.215.6678

Product: Midwest 245 Carbide Bur
Manufacturer: Dentsply Professional
Address: 901 W. Oakton St.
Des Plaines, IL 60018
Phone: 800.800.2888
Fax: 800.640.6165

Product: Authentic Press-To-Metal
Manufacturer: Microstar Corporation
Address: 1635 Lake Parkway
Suite J
Lawrenceville, GA 30043
Phone: 800.313.6427
Fax: 770.339.3188

Product: Authentic 86
Manufacturer: The Argon Corporation
Address: 5855 Oberlin Dr.
San Diego, CA 92121
Phone: 800.255.5524
Fax: 858.626.8686

Products: Fuji I Cement, Fuji Plus
Conditioner
Manufacturer: GC America Inc
Address: 3737 W. 127th St.
Alsip, IL 60803
Phone: 800.323.7063
Fax: 800.423.2963

Instructions

Contemporary Esthetics offers 12 Continuing Education (CE) credit hours per year. Each clinical CE article is followed by a 10-question, multiple-choice test, providing 1 hour of credit. To receive credit, record your answers on the enclosed answer sheet or submit them on a separate piece of paper. You may also phone your answers in to (888) 596-4605, or fax them to (703) 404-1801. Be sure to include your name, address, phone number, Social Security number, and method of payment. The deadline for submission of quizzes is 12 months after the date of publication. Participants must attain a score of 70% on each quiz to receive credit. To register, call (888) 596-4605. Participants are urged to contact their state registry boards for special CE requirements.

- | | | |
|---|---|---|
| <p>1. The Glickman and Stein study clearly showed the ideal way to alleviate excessive occlusal forces causing mobility of a tooth or teeth is to:</p> <p>a. splint the teeth.
b. brace the teeth with a swing lock RPD.
c. remove the destructive contacts.
d. brace the teeth with an orthodontic retainer.</p> <p>2. What offered a better option to create the proper overjet and provide more predicable results?</p> <p>a. Gold onlays
b. Placing permanent crowns
c. Acrylic veneers
d. Porcelain veneers</p> <p>3. What was the patient's main restorative goal?</p> <p>a. Esthetics
b. Phonetics
c. Form
d. "Fix" the abraded teeth.</p> | <p>4. During preparation, tapering the incisal edges enough created an overjet of approximately how long?</p> <p>a. 0.5 mm
b. 1.5 mm
c. 2.5 mm
d. 3.5 mm</p> <p>5. Where were all the margins placed?</p> <p>a. Slightly supragingivally
b. At the crest of the sulcus
c. 0.5 mm subgingivally
d. 1 mm subgingivally</p> <p>6. The acrylic temporary was removed using hemostats:</p> <p>a. after sectioning it.
b. before sectioning it.
c. during sectioning
d. in one piece.</p> <p>7. Conditioning the teeth before cementation is an important step to avoid what?</p> <p>a. Poor fitting crowns</p> | <p>b. Open margins
c. Plaque biofilm
d. Postoperative sensitivity</p> <p>8. When were all postoperative photographs taken?</p> <p>a. Immediately after cementation
b. 1 day after cementation
c. 1 week after cementation
d. 6 months after cementation</p> <p>9. It is difficult to gauge improvement when teeth are splinted without what?</p> <p>a. Impressions
b. Radiographs
c. Perioprobe sounding
d. Pre- and postsplinting photographs</p> <p>10. Splinting teeth to keep the weak ones around longer is a good plan only if:</p> <p>a. no other permanent options are possible.
b. there is limited room for a RPD.
c. the teeth are less than +1 mobile.
d. the patient's diet is limited to soft food.</p> |
|---|---|---|

Answer Form May 2005

CERP STATUS

Presently Enrolled in CE Program

Not Enrolled 1 exam completed = \$14.00

(PLEASE PRINT CLEARLY)

SSN --

ADA/AGD#: _____

Name _____

Address _____

City _____

State _____ Zip _____ Daytime Fax _____

Daytime Phone _____

Please make checks payable to
ASCEND MEDIA'S DENTAL LEARNING SYSTEMS
and mail with this form to: Dental Learning Systems CE Department,
405 Glenn Drive, Suite 4, Sterling, VA 20164-4432

CIRCLE ANSWERS

1.	a	b	c	d
2.	a	b	c	d
3.	a	b	c	d
4.	a	b	c	d
5.	a	b	c	d
6.	a	b	c	d
7.	a	b	c	d
8.	a	b	c	d
9.	a	b	c	d
10.	a	b	c	d

SCORING SERVICES

• By Mail

• Fax: 703-404-1801

• Phone-in:
888-596-4605
(9am-5pm ET, Mon.-Fri.)

• Customer Service
Questions? Please Call:
888-596-4605

Payment by Credit Card (Please use a Visa, MasterCard, or American Express Card)

Please enroll me in the *Contemporary Esthetics and Restorative Practice* Continuing Education Program marked below:
 Please enroll me in the 12-month CE Program for \$134 (a 20% saving versus paying for each exam individually).
Program includes all 12 exams in *Contemporary Esthetics and Restorative Practice* for 1 year (excluding supplements).

CHECK (payable to Ascend Media's Dental Learning Systems)

CREDIT CARD - Please complete information and sign below:

Card Number

Expiration Date: Mo/Y

/

Visa MasterCard American Express

SIGNATURE _____

DATE _____

PROGRAM EVALUATION

Please evaluate this issue's programs by responding to the following statements, using the scale of:
3 = Excellent to 1 = Poor.

- | | | | |
|---|----------------------|----------------------|----------------------|
| • Clarity of objectives | <input type="text"/> | <input type="text"/> | <input type="text"/> |
| • Usefulness of the content | <input type="text"/> | <input type="text"/> | <input type="text"/> |
| • Benefit to your clinical practice | <input type="text"/> | <input type="text"/> | <input type="text"/> |
| • Usefulness of the references | <input type="text"/> | <input type="text"/> | <input type="text"/> |
| • Quality of the written presentation | <input type="text"/> | <input type="text"/> | <input type="text"/> |
| • Quality of the illustrations | <input type="text"/> | <input type="text"/> | <input type="text"/> |
| • Clarity of review questions | <input type="text"/> | <input type="text"/> | <input type="text"/> |
| • Relevance of review questions | <input type="text"/> | <input type="text"/> | <input type="text"/> |

Please list future CE topic preferences: _____

- Did the lessons achieve their educational objectives? Yes No
- Did the articles present new information? Yes No
- How much time did it take you to complete the CE? _____ min

PRACTICE INFORMATION

- | | |
|--|--|
| <input type="checkbox"/> DDS/DMD | <input type="checkbox"/> Full-time registered Hygienist |
| <input type="checkbox"/> Dental Asst. | <input type="checkbox"/> Part-time registered Hygienist |
| <input type="checkbox"/> General Prac. | <input type="checkbox"/> Periodontist |
| <input type="checkbox"/> Oral Surgeon | <input type="checkbox"/> Prosthodontist |
| <input type="checkbox"/> Endodontist | <input type="checkbox"/> Other (includes dentists with nonspecified ADA specialty) |
| <input type="checkbox"/> Pedodontist | |

DEADLINE FOR SUBMISSION OF ANSWERS IS 12 MONTHS AFTER THE DATE OF PUBLICATION.